

## Trauma I - ABCs of Trauma

### **Triage and Transport**

Trauma patients are initially evaluated in the field by pre-hospital personnel. They are stabilized and transported to a suitable facility based on clinical status and the capabilities of the center. The method of transport is based on the severity of injury and the distance to the receiving facility. On arrival, patients are triaged based on the mechanism of injury, severity of injury, hemodynamic stability and resources available. In situations involving multiple victims, those with the most severe or life-threatening injuries are generally treated first. In situations where casualties overwhelm resources, however, patients that are unlikely to survive may receive expectant management in order to devote resources to patients with survivable injuries. Once appropriately triaged, trauma patients undergo assessment of vital signs, primary survey, secondary survey, resuscitation and definitive care.

### **Primary Survey**

The first component of the systematic approach to the trauma patient is called the primary survey. The purpose of the primary survey is to identify life-threatening injuries and initiate appropriate resuscitation. A simple mnemonic, ABCDE, is used to guide the steps of the primary survey. Evaluation of the severely injured patient must occur quickly and methodically to decrease the risk of missed injuries. Any decline in a patient's status warrants repeating the primary survey as clinical conditions in trauma can shift rapidly (1).

### **A - Airway Maintenance with Cervical Spine Protection**

The airway must be rapidly assessed for patency in all trauma patients. This can be done simply in awake patients by asking them to state their name and what occurred during the incident. If the patient has difficulty or is unable to speak, maneuvers include suctioning the oropharynx, searching for and removing foreign bodies, and identification of significant facial trauma or evidence of burn injury. Definitive airway management is required in the following scenarios:

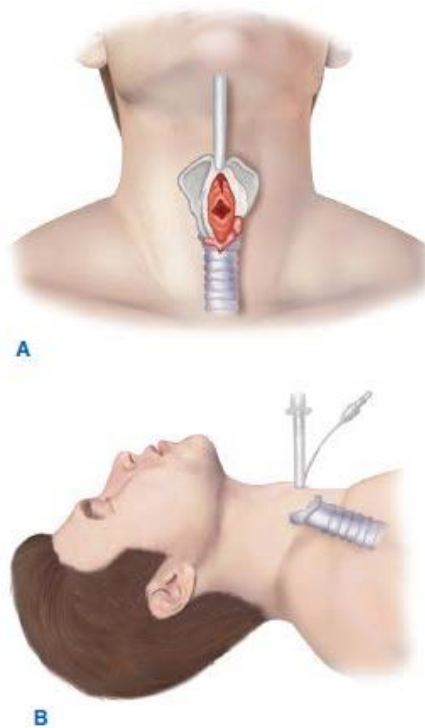
- Patients with depressed mental status or unable to protect their airway, such as patients with Glasgow Coma Scale (GCS) of 8 or lower.
- Patients with significant maxillofacial trauma at high risk for airway obstruction,
- Patients with severe hemodynamic instability.

In preparation for endotracheal intubation, simple maneuvers for opening the airway can be performed to improve oxygenation and ventilation. A jaw-thrust (chin-lifts are not used in blunt trauma patients given the need to protect the cervical spine) may be the most important initial procedure for an obtunded patient. An oral airway or nasal trumpet can be inserted. Finally, supplemental oxygen must be administered, usually by bag valve mask. In general, for obtunded or severely injured patients, it is preferable to establish a definitive airway with a cuffed endotracheal tube. Such tubes allow for oxygenation and ventilation in addition to preventing gastric contents or blood from entering the lower airways.

Methods for management of the airway include:

**Laryngeal mask airway (LMA)** - In cases where endotracheal intubation has been unsuccessful, a laryngeal mask airway can be placed as an advanced airway. This device is placed over the larynx and does not provide a definitive airway. Trauma patients who arrive from the field with an LMA require definitive airways upon arrival to a trauma center.

**Surgical airway** - In situations where endotracheal intubation is not feasible or unsuccessful after several attempts, a surgical airway can be performed. The most common emergent airway is obtained by incising the cricothyroid membrane and placing an endotracheal tube into the airway. In the case of cricothyroidotomy, the airway remains in place until a more definitive airway is established.



**Figure 1.** Cricothyroidotomy performed via vertical skin incision. The cricothyroid membrane is incised transversely and an endotracheal tube is inserted into the airway. (2)

**Endotracheal intubation** - The most common definitive airway in trauma is endotracheal intubation. This can be performed with the aid of direct laryngoscopy, fiberoptic bronchoscopy, video laryngoscopy, or a number of other methods.

As trauma patients are at high risk for aspiration, rapid sequence intubation is recommended to decrease likelihood of aspiration of gastric contents. Patients undergo pre-oxygenation, cricoid pressure, administration of rapid-onset sedative or hypnotic agents, neuromuscular-blockade to induce paralysis, followed immediate introduction of the endotracheal tube. Following placement

of the endotracheal tube, the first priority is to confirm its position within the trachea. End-tidal CO<sub>2</sub> verification with disposable testing devices or continuous monitors provide the most reliable means of accomplishing this.

Regardless of the intervention utilized to evaluate and establish the airway, great care must be taken to avoid exacerbating a potential cervical spine injury. Hard collars and neck immobilization can prevent spinal cord injury in these patients. Collars should remain in place until injury to the cervical spine is effectively ruled out. Manual in-line stabilization can be performed if the collar needs to be removed for intubation (1).

### **B - Breathing and Ventilation**

After assessing and securing the airway, the next step is to ensure there are no barriers preventing ventilation and oxygenation. The examiner should evaluate for symmetrical chest rise, tracheal position, jugular venous distention, audible breath sounds, and evidence of trauma to the chest wall. There are several specific injuries that must be rapidly identified and dealt with should they be present. They include tension pneumothorax, massive hemothorax, and open pneumothorax (also referred to as “sucking” chest wound).

Diagnosis of each is based on clinical findings and prompts immediate intervention.

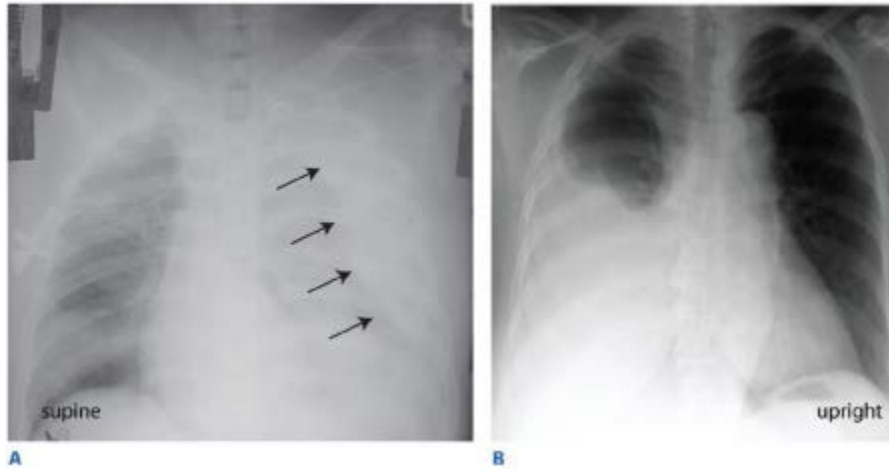
***Tension Pneumothorax*** - Clinical signs associated with tension pneumothorax include absent breath sounds, jugular venous distention, tracheal deviation away from the injured side, and hypotension. Tension pneumothorax differs from simple pneumothorax in that the injured portion of lung parenchyma acts as one-way valve allowing air to enter the pleural space with each breath. The flap closes with exhalation resulting in ever increasing intrathoracic pressure. The trachea and mediastinal structures may deviate away from the affected side which ultimately occludes the superior and inferior vena cava. The loss of venous return to the heart results in obstructive shock and hypotension.

The diagnosis of tension pneumothorax should be made before obtaining a chest radiograph. Prompt tube thoracostomy should be performed to decompress the chest and reestablish normal venous return. Needle decompression, usually with a 14-gauge catheter in the second intercostal space, mid-clavicular line, may be performed in the field, but is generally not appropriate in the trauma bay where a chest tube can be placed rapidly (1).

***Hemothorax*** - Hemothorax is defined as blood contained within the pleural cavity. The source bleeding may be from an injured intercostal vessel in the setting of rib fractures, pulmonary laceration, pulmonary hilar injury, or great vessel laceration. The quantity of blood may range from an amount barely visible on chest radiograph, to several liters resulting in compression of the lung and “white-out” of the affected side on chest x-ray. Patients with massive hemothorax may have flat neck veins, absent breath sounds on the affected side, and hemodynamic instability secondary to hemorrhagic shock.

Initial management includes aggressive resuscitation and replacement of blood products and decompression of the chest with a chest tube. Patients with large volumes of blood evacuated will often require urgent thoracotomy for hemorrhage control (1, 2). Typical indication for

thoracotomy includes initial evacuation of 1500 mls. of blood or ongoing output of 250 ml/hour for three consecutive hours.



**Figure 2.** Chest x-ray of hemothorax in supine (A) and upright (B) positions. Blood layers posteriorly while the patient is supine. It can be seen collecting dependently in the upright position (2).

**Open Pneumothorax (“Sucking” Chest Wound)** - A defect in the chest wall that allow air to enter into the thoracic cavity is termed open pneumothorax. If the wound is 2/3 of the diameter of the trachea or larger, air will preferentially enter through the chest wall defect inhibiting ventilation. A simple procedure to restore normal respiratory mechanics is placement of an occlusive dressing taped on three sides over the defect. A flutter valve is created preventing air from entering the chest on inspiration while allowing it to evacuate during exhalation. A completely occlusive dressing without the presence of a chest tube could result in a tension pneumothorax. Chest tubes should be placed in a location remote from the chest wound.

A chest x-ray should be performed as part of the assessment of breathing after the primary survey is completed and can help to confirm proper endotracheal or chest tube placement and recognition of pneumothorax or hemothorax not detected on exam. Treatment of these serious injuries, if there is clinical suspicion, should not be delayed for x-ray (1).

### **C - Circulation with Hemorrhage Control**

Assessment of circulation entails evaluating a patient’s volume status as well as obtaining adequate intravenous access and controlling sources of bleeding. Vital signs provide valuable information regarding a patient’s physiologic response to an injury. Tachycardia in adults is defined as a heart rate of 100 beats per minute or greater. A trauma patient may become tachycardic due to pain or stress, but shock, as a result of hemorrhage, must be suspected in any injured patient. Changes in blood pressure, such as a decreased systolic pressure or widened pulse pressure, can also suggest that a patient is in some degree of hemorrhagic shock. Hypotension is defined as systolic pressure less than 90 mm Hg. The combination of hypotension and tachycardia is often referred to as hemodynamic instability. Prompt recognition of stability is important as it strongly affects the management of trauma patients.

**ACS/ASE Medical Student Core Curriculum**  
**Trauma I - ABCs of Trauma**

Whenever possible, it is important to obtain a report from first responders. This may aid in understanding mechanisms of injury that may help identify injury patterns. General physical exam findings of a patient in hemorrhagic shock include altered level of consciousness or anxiety, pallor or coolness of the skin, or a rapid or weak central pulse. While external hemorrhage is a common source of significant blood loss, these injuries are usually easily identified in the field or trauma bay. External hemorrhage can often be controlled with direct pressure or a tourniquet until definitive control can be obtained in the operating room. This is more common in penetrating trauma.

If the source of hemorrhage is not evident, which is more often the case in blunt trauma, there are five compartments that can accommodate large enough volumes of blood to result in hemodynamic instability:

- thoracic cavity
- peritoneal cavity
- retroperitoneum
- pelvis
- long bones (usually femur fractures)

Patient history, vital signs, and physical exam findings will help the astute clinician make an assessment of volume status. Physical exam findings such as a distended abdomen, unstable pelvis, or lower extremity deformity must alert the examiner to the possibility of significant hemorrhage. Adjuncts to the physical exam should be employed to evaluate each area. In the unstable blunt trauma patient, chest x-ray, pelvis x-ray and FAST (Focused Assessment with Sonography in Trauma) can be performed quickly in most situations. It is difficult to identify hemorrhage in the retroperitoneum with these modalities and it may require exploratory laparotomy for diagnosis and treatment. Computed tomography is effective for identifying sources of hemorrhage in hemodynamically stable patients. However, this imaging modality is generally contraindicated in cases of hemodynamic instability.

<b>Imaging Modality</b>	<b>Common Findings</b>	<b>Cause of instability</b>	<b>Trauma Bay Treatment</b>
Chest X-ray	Widened mediastinum, effusion, rib fractures, mediastinal deviation, pneumothorax	Pneumothorax, hemothorax, aortic injury	Chest tube
Pelvis X-ray	Pelvic fractures, widened pubic symphysis (open book)	Pelvic blood vessel disruption	Pelvic binder
FAST	Fluid in pericardium, Morrison's (hepatorenal) pouch, splenorenal space, and pelvis	Pericardial tamponade, hemoperitoneum	Transport to OR for Sternotomy, laparotomy
Extremity X-ray	Long bone fracture	Peripheral vascular bleeding	Reduction/tourniquet

**Table 1.** Imaging in unstable patients

Large bore, generally 16-gauge and larger, peripheral intravenous access is preferred for large volume resuscitation. Internal diameter and length of the line determine the maximum rate at which a fluid may be given. Short, large bore peripheral angiocatheters are therefore superior to longer central venous catheters with smaller internal diameters for large volume resuscitation. If peripheral venous access cannot be obtained, central resuscitative lines can be placed in the internal jugular, subclavian or femoral veins. If this is not technically feasible, intraosseous lines can be placed and used effectively for resuscitation (1).

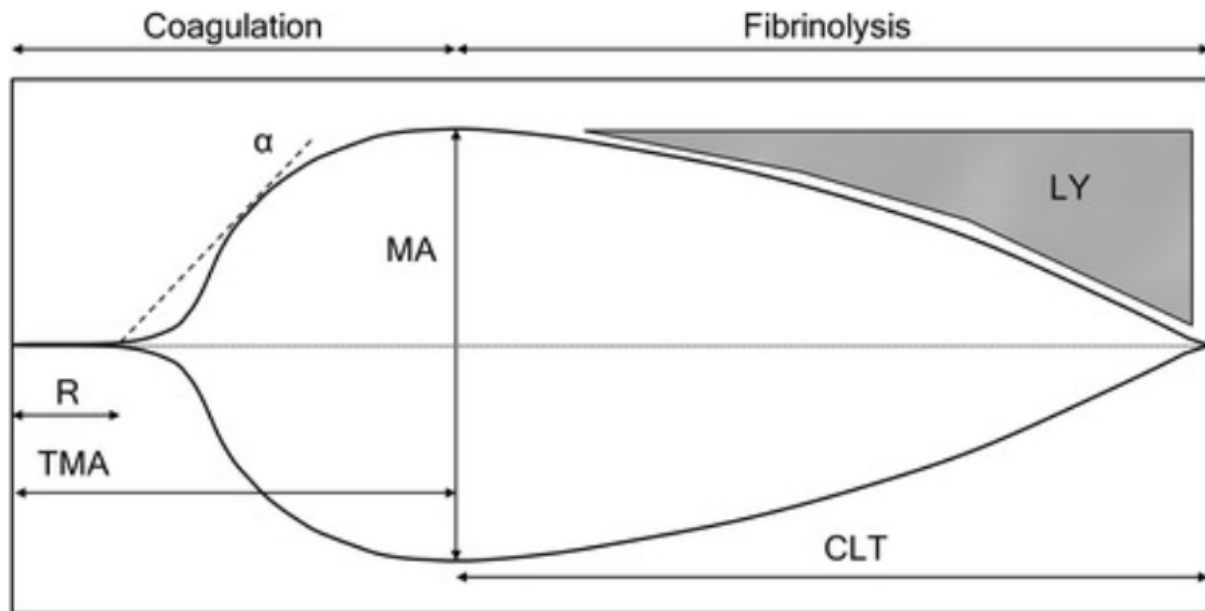
Hemorrhagic shock is the most common form of shock seen in the trauma patient. Once obstructive shock from tension pneumothorax or pericardial tamponade have been ruled out, resuscitative efforts are directed towards replacing blood volume and control of hemorrhage.

### Classes of Shock

	Class I	Class II	Class III	Class IV
Blood loss (mL)	Up to 750	750-1500	1500-2000	>2000
Blood loss (%BV)	Up to 15%	15%-30%	30%-40%	>40%
Pulse rate	<100	>100	>120	>140
Blood pressure	Normal	Normal	Decreased	Decreased
Pulse pressure (mm Hg)	Normal or increased	Decreased	Decreased	Decreased
Respiratory rate	14-20	>20-30	30-40	>35
Urine output (mL/h)	>30	>20-30	5-15	Negligible
CNS/mental status	Slightly anxious	Mildly anxious	Anxious and confused	Confused and lethargic

**Table 2.** (2)

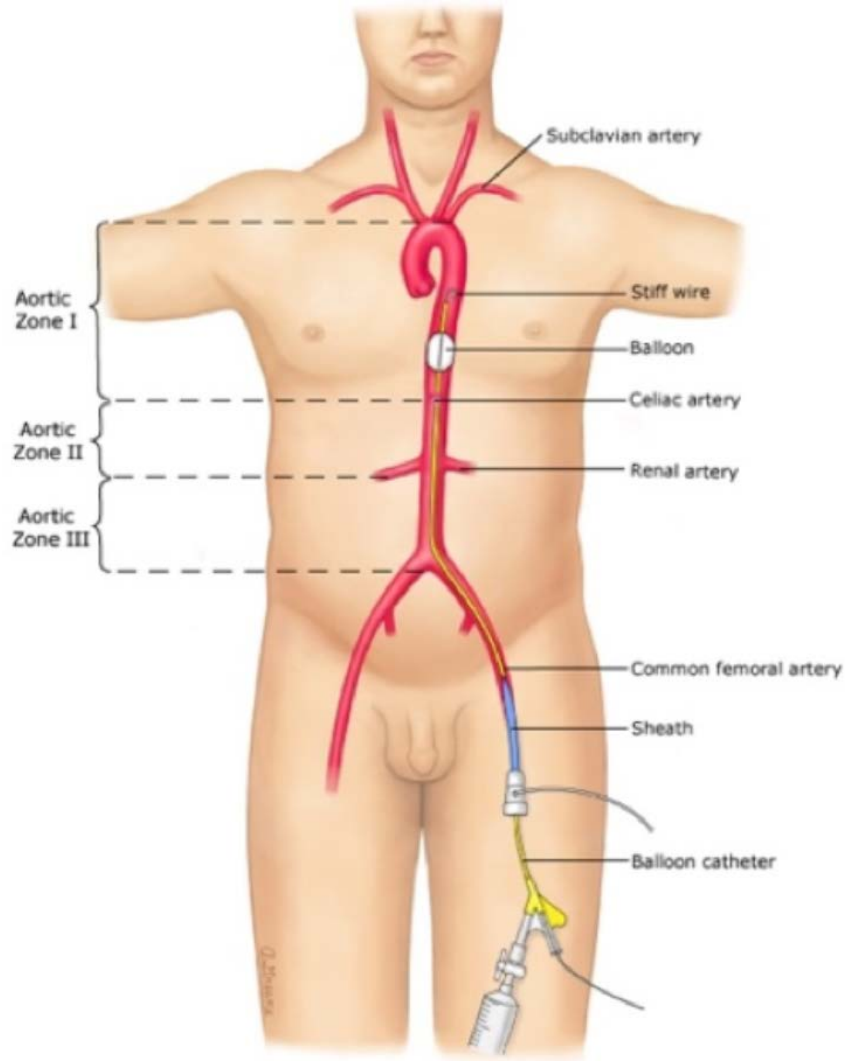
Unstable patients who have sustained significant blood loss may require large amounts of blood product very rapidly. Massive transfusion protocols have been developed to efficiently supply large amounts of blood product to the injured patient. Packed red blood cells, fresh frozen plasma and platelets are generally given in a 1:1:1 ratio. Thromboelastography (TEG) guides resuscitation by assessing the characteristics of a patient's clot formation and breakdown (4). Aberrations in these values can guide the surgeon in determining which blood products to use in reeducation.



**Figure 3.** Diagram of thromboelastogram. R = reaction time, alpha = angle, MA = maximum amplitude, TMA = time to maximal amplitude, LY = percentage amplitude reduction, CLT = clot lysis time (7).

Emergency department thoracotomy can be performed in select patients presenting in extremis. Goals of ED thoracotomy include evaluation of the pericardium with decompression of tamponade, identification and repair of penetrating cardiac injury, and cross-clamping the descending thoracic aorta. Indications for thoracotomy in the ED differ for blunt versus penetrating mechanisms. In general, patients with penetrating injuries have a higher likelihood of survival than patients with blunt injuries undergoing ED thoracotomy (5).

A newer method of temporizing severe hemorrhage below the level of the diaphragm is resuscitative balloon occlusion of the aorta (REBOA). This technique involves placing a sheath in the common femoral artery followed by deploying an endovascular balloon that can be inflated in the lumen of the aorta to decrease arterial bleeding. REBOA allows for occlusion of the aorta without the added morbidity opening the thoracic cavity (3).



**Figure 4.** REBOA with balloon inflated in zone I of the aorta. (6)

### **D - Disability (Neurologic Evaluation)**

Rapid assessment of the patient's neurologic status is an important part of the primary survey. Details of the event such as loss of consciousness raise suspicion for potential intracranial injury. Providers should also determine patient's mental status and whether they take any antiplatelet or anticoagulant medications.

Physical exam methods used to evaluate neurologic function include measuring pupillary size and reaction, assessing level of consciousness, and application of the Glasgow Coma Scale.

The Glasgow Coma Scale can be utilized quickly and is useful for initial assessment as well as prognosis. GCS can be repeated throughout the patient's course to track progress or identify signs of decompensation. The score is calculated by adding the best responses from each of the three components of the scale.



**ACS/ASE Medical Student Core Curriculum  
Trauma I - ABCs of Trauma**

A rapid assessment of the patient’s ability to move all extremities can provide information regarding the presence of a spinal cord injury. If injury to the cord is suspected, a more detailed exam can help determine the level at which the cord is affected.

Depressed neurologic status can be present secondary to direct injury to the central nervous system, alcohol intoxication, shock, or a number of other factors. In the setting of traumatic brain injury, initial priority is to avoid secondary brain injury resulting from hypoxemia and hypoperfusion to the brain (1, 2).

**Glasgow Coma Scale**

<b>Eye Opening</b>	4	Spontaneous
	3	To voice
	2	To pain
	1	None
<b>Verbal</b>	5	Oriented
	4	Confused
	3	Inappropriate words
	2	Incomprehensible words
	1	None
<b>Motor Response</b>	6	Obeys commands
	5	Localizes to pain
	4	Withdraws
	3	Abnormal flexion
	2	Abnormal extension
	1	None

**Table 3. (2)**

**E - Exposure and Environmental Control**

The final portion of the primary survey focuses on completely exposing the patient to avoid missing injuries. All clothing is removed and the patient is turned in order to examine the back and posterior surfaces. Once the patient is undressed, they should be covered with warm blankets in order to prevent loss of body heat. Other means to prevent hypothermia in trauma patients include increasing the ambient temperature of the trauma room, infusion of warmed intravenous fluids, or placement of an external warming device.

Patients that have been exposed to skin irritants or other hazards substances should also be decontaminated to prevent burns and progressive injury. Clothing soaked in gasoline is promptly removed and discarded. Trauma centers also utilize decontamination rooms to wash harmful substances from the patient’s body (1).

**Secondary Survey**

The secondary survey takes place once the primary survey is complete and resuscitation is in progress. It includes a systematic, head-to-toe history and physical exam. Each body region is examined carefully to avoid missing an injury. Radiography and computed tomography scans are also utilized as part of the secondary survey.

**ACS/ASE Medical Student Core Curriculum  
Trauma I - ABCs of Trauma**

Efforts must be taken to discover the patient's medical background as well as details of the event surrounding the trauma. A simple acronym to remember the important components of the history is as follows:

- S** - Signs/symptoms
- A** - Allergies
- M** - Medications
- P** - Pertinent past medical history
- L** - Last oral intake
- E** - Events leading to the illness or injury

In the case of comatose or unresponsive patients, details of the history should be obtained from family members or emergency medical personnel. A description of the patient's mechanism of injury is critical as the pattern of injury may guide the workup and management and avoid missed injuries (1).

**Secondary Survey**

Anatomic Region	Exam Findings	Possible Injuries
Head	Bleeding, skin defects, loss of vision, decreased extraocular motion, hemotympanum	Scalp laceration, trapped extraocular muscle, basilar skull fracture
Face	Midface stability, malocclusion, skin defects, bleeding from nares	Facial and mandibular fractures, nasal septal hematoma, dental injury
Neck	Cervical spine tenderness, hematoma, bruit, tracheal position, seat belt mark	Cervical spine fracture, penetrating and blunt vascular injuries, esophageal and tracheal injuries
Chest	Breath sounds, crepitus, chest wall stability, symmetrical chest wall motion, chest wall defects	Pneumothorax, rib fractures, hemothorax, open pneumothorax, sternal fracture
Abdomen	Distention, tenderness, peritoneal signs, seat belt mark	Solid organ injury, hollow viscus injury, vascular injury
Pelvis and Perineum	Pelvic stability, blood at meatus, scrotal hematoma, rectal exam, high riding prostate	Pelvic fracture, urethral disruption, rectal injury
Back	Skin defects, thoracic or lumbar spine tenderness or step-offs, flank hematoma	Spine fracture
Neurologic	Mental status, strength, sensation	Intracranial injury, spinal cord injury, peripheral nerve damage
Extremities	Distal pulses, gross bone deformity, joint stability, compartment firmness	Long bone fractures, peripheral vascular injury, compartment syndrome, ligamentous injuries

**Table 4. (1)**

### Tertiary Survey

The tertiary survey serves as the final means of identifying injury in the trauma patient. It typically takes place within 24 hours of the injury. The primary and secondary surveys are repeated and all laboratory and imaging data are reviewed. Any new injuries should be identified and proper imaging obtained if indicated.

### Questions

1. A 26-year-old male presents to the trauma bay after being involved in a high-speed motorcycle collision. You note that he is obtunded and has bilateral open lower extremity fractures with exposed bone and muscle. What is the first priority when first assessing this patient?
  - A. Place tourniquets on both lower extremities to control bleeding.
  - B. Place two large bore peripheral IV lines.
  - C. Assess the airway and, if necessary, perform endotracheal intubation.
  - D. Send the patient to the CT scanner to look for intracranial injury.
2. You are evaluating a 22-year-old male following blunt trauma. His blood pressure is 84/47 and heart rate is 134. He is alert but anxious, complaining of abdominal pain. You obtain intravenous access and begin transfusion of blood products. What is the next best step?
  - A. Chest x-ray, pelvis x-ray and FAST exam to look for sources of hemorrhage.
  - B. Emergent CT scan of the chest, abdomen, and pelvis.
  - C. Transport the patient to the operating room for exploratory laparotomy.
  - D. Place a pelvic binder.
3. You have completed the primary and secondary surveys for a 47-year-old man who was struck by a motor vehicle while riding his bicycle. You found him to be hemodynamically stable with a GCS of 15. His only obvious injury is a deformed right shoulder. The nurse suddenly alerts you that the patient has become unresponsive and his systolic blood pressure has now dropped into the 60's with a palpable carotid pulse. What is the next best step?
  - A. Call a code blue.
  - B. Begin chest compressions.
  - C. Re-evaluate the patient starting with another primary survey.
  - D. Perform urgent reduction of his dislocated shoulder.

4. A 19-year-old male was struck by a truck while crossing the street. Blood pressure is 76/34 and heart rate is 122. You secure the airway and obtain a chest x-ray that suggests pulmonary contusions on the right and a FAST exam showing a black stripe between the liver and right kidney. What is the next best step?
  - A. Go to the operating room for abdominal exploration.
  - B. Perform emergency department thoracotomy.
  - C. Place a central line, arterial line, and Foley catheter.
  - D. Obtain CT scans of the chest, abdomen, and pelvis.
  
5. A 22-year-old male presents to the Emergency Department after being stabbed multiple times in the chest and abdomen. He is hemodynamically stable. During the primary survey, special attention must be given to which of the following:
  - A. Obtain a detailed history and physical.
  - B. Assess pelvis for stability to compression.
  - C. Expose and roll the patient to identify additional wounds.
  - D. Draw CBC, CMP, and PT/INR.

**Answers**

1. A 26-year-old male presents to the trauma bay after being involved in a high-speed motorcycle collision. You note that he is obtunded and has bilateral open lower extremity fractures with exposed bone and muscle. What is the first priority when first assessing this patient?
  - A. Place tourniquets on both lower extremities to control bleeding.
  - B. Place two large bore peripheral IV lines.
  - C. Assess the airway and, if necessary, perform endotracheal intubation.**
  - D. Send the patient to the CT scanner to look for intracranial injury.
  
2. You are evaluating a 22-year-old male following blunt trauma. His blood pressure is 84/47 and heart rate is 134. He is alert but anxious, complaining of abdominal pain. You obtain intravenous access and begin transfusion of blood products. What is the next best step?
  - A. Chest x-ray, pelvis x-ray and FAST exam to look for sources of hemorrhage.**
  - B. Emergent CT scan of the chest, abdomen, and pelvis.
  - C. Transport the patient to the operating room for exploratory laparotomy.
  - D. Place a pelvic binder.
  
3. You have completed the primary and secondary surveys for a 47-year-old man who was struck by a motor vehicle while riding his bicycle. You found him to be hemodynamically stable with a GCS of 15. His only obvious injury is a deformed right shoulder. The nurse suddenly alerts you that the patient has become unresponsive and his systolic blood pressure has now dropped into the 60's with a palpable carotid pulse. What is the next best step?
  - A. Call a code blue.
  - B. Begin chest compressions.
  - C. Re-evaluate the patient starting with another primary survey.**
  - D. Perform urgent reduction of his dislocated shoulder.
  
4. A 19-year-old male was struck by a truck while crossing the street. Blood pressure is 76/34 and heart rate is 122. You secure the airway and obtain a chest x-ray that suggests pulmonary contusions on the right and a FAST exam showing a black stripe between the liver and right kidney. What is the next best step?
  - A. Go to the operating room for abdominal exploration.**
  - B. Perform emergency department thoracotomy.
  - C. Place a central line, arterial line, and Foley catheter.
  - D. Obtain CT scans of the chest, abdomen, and pelvis.

**ACS/ASE Medical Student Core Curriculum**  
**Trauma I - ABCs of Trauma**

5. A 22-year-old male presents to the Emergency Department after being stabbed multiple times in the chest and abdomen. He is hemodynamically stable. During the primary survey, special attention must be given to which of the following:
  - A. Obtain a detailed history and physical.
  - B. Assess pelvis for stability to compression.
  - C. **Expose and roll the patient to identify additional wounds.**
  - D. Draw CBC, CMP, and PT/INR.

**References**

1. Advanced Trauma Life Support Student Course Manual. American College of Surgeons Committee on Trauma. 9e. 2012.
2. Burlew C, Moore E. Trauma. In: Brunickardi F, Andersen DK, Billiar TR, Dunn DL, Hunter JG, Matthews JB, Pollock RE. eds. Schwartz's Principles of Surgery, 10e. New York, NY: McGraw-Hill; 2014.
3. Dubose J, Scalea T, Brenner M, et al. The AAST prospective Aortic Occlusion for Resuscitation in Trauma and Acute Care Surgery (AORTA) registry: Data on contemporary utilization and outcomes of aortic occlusion and resuscitative balloon occlusion of the aorta (REBOA). J Trauma Acute Care Surg. 2016.
4. Gonzalez E, Moore E, Moore H, et al. Goal-directed Hemostatic Resuscitation of Trauma-induced Coagulopathy: A Pragmatic Randomized Clinical Trial Comparing a Viscoelastic Assay to Conventional Coagulation Assays. Annals of Surgery. June 2016.
5. Seamon M, Haut E, Van Arendonk K, et al. Emergency Department Thoracotomy. J Trauma. July 2015.
6. Katz N. REBOA: Resuscitative Endovascular Balloon Occlusion of the Aorta. [emottawablog.com/2017/02/reboa-resuscitative-endovascular-balloon-occlusion-of-the-aorta/](http://emottawablog.com/2017/02/reboa-resuscitative-endovascular-balloon-occlusion-of-the-aorta/). February 2017.
7. Ronsholt F, Gerstoff J, Ullum H, et al. Thromboelastography on plasma reveals delayed clot formation and accelerated clot lyses in HIV-1 infected persons compared with healthy controls. BMC Infectious Diseases. September 2015.