

Introduction to Ultrasound

Date: Thursday, September 20, 2018

Time: 1:00 PM

Location: **Lecture Hall SSOM Room 190**

Watch → Medical Student Introduction to Bedside Ultrasound Physics and Knobology:

<https://www.youtube.com/watch?v=RDqWK-DzPus&list=PL3Zty8IubWpexaYymphlUdPrnlsVBR-Oi&index=8>

Faculty Info: Amy Kule, MD – akule@lumc.edu

LEARNING OBJECTIVES

- Understand how to maneuver around the ultrasound machine regarding button location and functionality
- Describe transducer differences and appropriate selection
- Describe various scanning modes
- Understand function and adjustment of frequency, depth and gain to optimize image capture
- Understand scanning terminology: hyperechoic, hypoechoic, anechoic
- Describe and demonstrate scanning planes: longitudinal (sagittal), transverse (axial), coronal

HANDS-ON OBJECTIVES

- Turn machine on
- Choose and activate appropriate transducer
- Place probe and indicator in correct orientation
- Adjust depth
- Adjust gain

INTRODUCTION TO ULTRASOUND

Why Ultrasound? – Portable, fast, inexpensive, non-invasive, no ionizing radiation

Limitations of Ultrasound – Depends on skill of user (“operator-dependent”) and patient body habitus. Ultrasound does not pass well through bone, and is scattered by air

ALARA (As Low As Reasonably Achievable) – A philosophy of radiation use based on keeping exposure as low as possible.

How Does Ultrasound Work? – Piezoelectric Effect

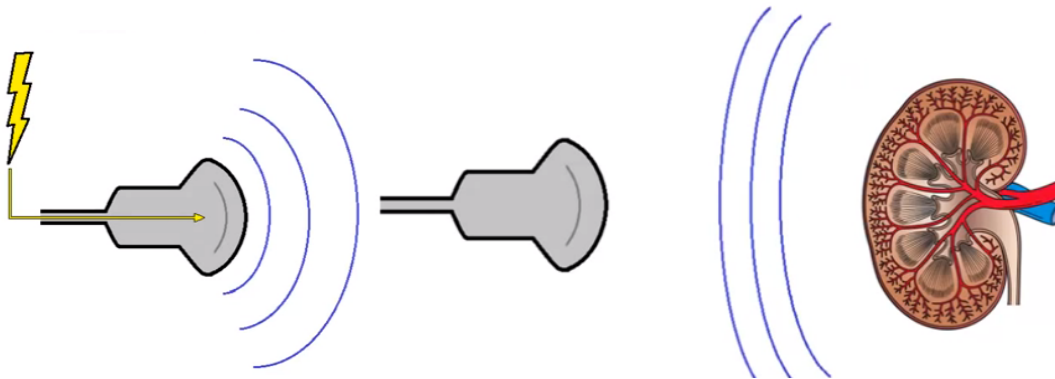


Image Credit: Eric Shappell Loyola '13

When electricity is applied to piezoelectric crystals, the vibrations produce sound waves that travel outward. The waves hit objects and bounce back to the piezoelectric crystals, and the mechanical energy produced from the vibration of the crystal is converted into electrical energy. The ultrasound machine calculates the time it takes for sound waves to travel back to the probe and produces a gray-scale image on the screen.

Knobology:

- Find 'ON' button
- Depth
- Gain

Probes:

- Linear, Curvilinear, Phased Array, Endocavitary
- High frequency probes vs Low frequency probes (Resolution, Penetration)

Basic Motions:

- Sweep
- Slide
- Fan
- Rotate
- Rock (Heel-Toe)

Ultrasound Convention:

- Probe marker (Bump) to the patient's right or head

Scanning Planes:

- Longitudinal (Sagittal)
- Transverse (Axial)
- Coronal

Basic Terms:

- Echogenic – Structure or medium capable of reflecting or transmitting ultrasound waves, creating a brighter image
- Anechoic – Image appears dark (black)
Example: Fluid-filled structures such as bladder, blood vessel
- Hyperechoic – Ultrasound Image Appears Brighter Than Surroundings (White)
Example: Bone
- Hypoechoic - Ultrasound image appears darker than surrounding structures
- Isoechoic – Ultrasound image appears similar in brightness to surrounding structures

Additional Resources:

1. **Ultrasound Fundamentals** Video by Eric Shappell (SSOM '13)
<http://www.youtube.com/watch?v=RXvvQYONlmE>
2. <http://www.ncbi.nlm.nih.gov/pmc/articles/PMC3063344/>