<u>Trauma to the Nervous System</u> (Dr. Merchut)

1. Pathophysiology of head trauma

A more diffuse force applied to the skull typically produces a linear skull fracture, while a more focal or localized force causes a depressed skull fracture. A severe **skull fracture** may be associated with an underlying contusion (bruise) or laceration of the brain. Fractures at the skull base, face or orbit can entrap or compress cranial nerves. Leakage of cerebrospinal fluid (CSF) from the ear or nose may signal a greater risk of infection developing in the CSF or brain itself. Treatment involves surgical removal of bone fragments and debris, and closure of any dural tears.

Brain contusions are superficial hemorrhages at the tops of cortical gyri, near the point of impact (coup) or more remotely in the brain (contrecoup) from movement of the brain within the skull. They **occur most often at the basal or ventral surfaces of the frontal and anterior temporal lobes** (Figure 1), where the bony skull is roughened (orbital surface of frontal bone) or protuberant (edges of sphenoidal wings). Brain contusions are **caused by angular or rotational, not linear, acceleration of the brain** (which explains why the woodpecker survives without brain injury).

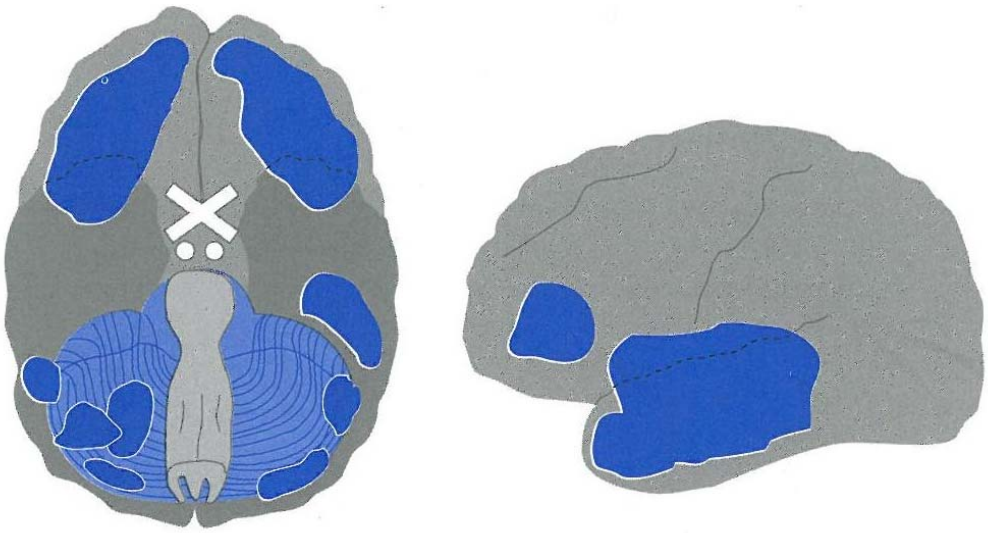

Figure 1. Frequency distribution of brain contusions. Individual cases are outlined and superimposed. (From Gurdjian ES. *J Trauma* 16[1]:35-51, 1976.)

Contusions or more severe intracranial hemorrhages are often associated with **brain edema**, due to local metabolic or ischemic processes in addition to the presence of blood. Increased intracranial pressure (ICP) decreases cerebral blood flow, creating ischemia, and compensatory cerebral autoregulation eventually fails if the edema progresses. **Cerebral autoregulation** (vasoconstriction or vasodilatation) is the preservation of optimal cerebral blood flow despite fluctuation in systemic blood pressure over a range of 60 to 140 mm Hg (mean arterial pressure). In the setting of severely increased ICP, **Cushing's response** (or Cushing's reflex) may be observed, indicated by **elevation of systemic blood pressure** to preserve cerebral blood flow. This is accompanied by a parasympathetic response of **bradycardia and slowed respiratory rate**. Local cerebral edema may shift or herniate brain at typical sites (Figure 2). The cingulate gyrus may be pushed beneath the unyielding falx cerebri (**subfalcine herniation**). The medial temporal lobe (uncus) may be compressed against the midbrain (**uncal herniation**), causing a fixed and dilated ipsilateral pupil. Shifting of the lower brain stem and cerebellar tonsils down the foramen magnum (**tonsillar herniation**) becomes fatal as the medullary cardiorespiratory centers fail.

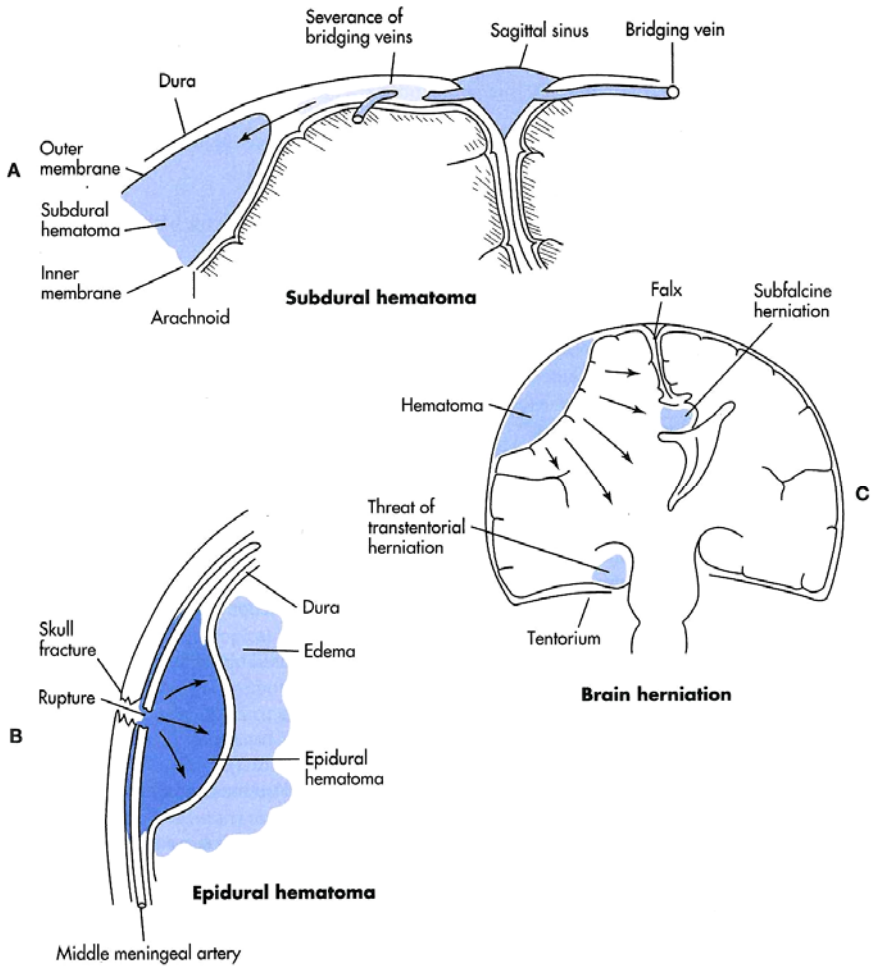

Figure 2. Subdural (A) and epidural (B) hematomas with subsequent herniation (C). (From Willard RH, Perl DP. *Medical Neuroanatomy*. Philadelphia:JB Lippincott, 1993)

2. Types of traumatic intracranial hemorrhage

An **acute subdural hematoma** occurs after the focal laceration of bridging cortical veins, which empty into larger venous sinuses of the brain. Clot thus forms beneath the dura and compresses underlying cerebral cortex (Figure 2). Depending on the size and progression of the bleeding, patients vary from an asymptomatic state to focal neurological deficits to coma. The prognosis is worse in the presence of other cerebral hemorrhages or multiple contusions. Treatment consists of surgical removal of the hematoma after emergent brain imaging. The elderly atrophic brain is more susceptible since the cortical bridging veins are stretched over a larger subdural space, and subdural bleeding can occur after minimal head trauma. A **chronic subdural hematoma** may thus develop in an elderly patient after repeated, often mild, head injuries. A subdural collection of fresh blood and serous fluid from previous bleeding gradually accumulates and enlarges. Patients may have subtle headaches, confusion or altered mental status rather than obvious focal neurological deficits. The diagnosis is difficult but **should always be considered in a confused, elderly patient**, where chronic subdural hematomas may be bilateral. Chronic subdurals may also occur in infants or children who are repeatedly beaten or abused. Treatment consists of surgical removal of the clot, and often its surrounding fibrous capsule as well.

An **epidural hematoma** usually occurs from rupture of a meningeal artery or vein, or rarely from a torn venous sinus. Clot forms between the skull and dura (Figure 2), often after a temporal bone fracture lacerates the middle meningeal artery. The classical or textbook clinical presentation may actually be uncommon: initial loss of consciousness followed by a lucid interval, then neurological worsening. The treatment again is surgical removal of the clot.

Cerebral hemorrhages within the brain parenchyma vary in size and severity, with focal neurological deficits dependent on their location. Surgical procedures to remove these deeper clots may be ill-advised since critical areas of brain could be damaged in doing so. These patients are observed in neurosurgical intensive care units where ICP is monitored. The medical treatment of increased ICP follows from the **Monro-Kellie doctrine**, which describes intracranial volume as the sum of brain, vascular and CSF volumes. Since an intact skull maintains a constant intracranial volume, the development of brain edema increases the ICP. **Mechanical hyperventilation** reduces arterial pCO_2, which causes cerebral arterial vasoconstriction, and thus a reduced intracranial blood volume and reduced ICP. **Osmotic diuretics**, such as mannitol, reduce elevated ICP by removing water across the intact blood-brain barrier of normal brain tissue, serving to reduce brain volume.

3. Evaluation and treatment of head trauma patients

In critically injured patients, immediate attention is given to the **ABCs** of **airway, breathing and circulation**, with subsequent evaluation of injuries to the head, spine, and thoracoabdominal organs. The cervical spine must be immobilized until imaging studies have excluded a fractured or unstable spinal column. Serial neurological exams are recorded, including use of the Glasgow Coma Scale (Table 1), which helps estimate the prognosis for recovery. Urgent transport to a trauma center with neurosurgical staff may

be needed once the patient is hemodynamically stabilized. Except for deeper brain hemorrhages, most symptomatic subdural or epidural hematomas are surgically removed.

Patients with mild head trauma may have a **concussion**, previously defined as a brief, transient loss of consciousness without persistent neurological deficit. The current, updated definition of concussion is a trauma-induced alteration in mental status that may or may not involve loss of consciousness, but typically includes a brief period of confusion and amnesia. For athletes and military personnel, recovery begins with removal from sport or combat, and a period of rest and therapy depending on the severity of the injury. Physical activity is gradually resumed, or avoided indefinitely in the setting of severe or multiple head injuries. It is becoming clearer that repeated concussions often lead to permanent losses of cognitive or neurological function. Movement of the brain within the skull may also cause the **postconcussion syndrome**, which takes days to weeks to gradually resolve. Patients report headache or neck ache, impaired concentration or memory, and positional dizziness or vertigo. Stretched cranial nerves may cause diplopia. Brain CT or MRI scans are normal, however. **Major head injury may lead to chronic cognitive, behavioral or neurological deficits**, persistent even after any hematoma or bleeding is resolved. There may be minimal or no obvious lesions on brain imaging, but microscopically there is diffuse shearing of cerebral white matter with axonal damage and retraction, as well as ischemic neuronal damage from previously impaired cerebral blood flow. Post-traumatic epilepsy may also develop and require anticonvulsant therapy. Most of these patients need long term, multi-modality rehabilitation.

Table 1. Glasgow Coma Scale

Parameter	Response	Score
A. Eye opening	Spontaneously	4
	To verbal command	3
	To pain	2
	None	1
B. Best motor response	Obeys verbal commands	6
	Localizes pain	5
	Withdraws from pain (flexion)	4
	Shows abnormal flexion (decorticate rigidity)	3
	Shows abnormal extension (decerebrate rigidity)	2
	None	1
C. Best verbal response	Oriented and converses	5
	Disoriented and converses	4
	Uses inappropriate words	3
	Makes incomprehensible sounds	2
	No response	1
Total (highest scores of A, B, and C)		3-15

4. Spinal cord trauma

Spinal cord neurons may be damaged from trauma in several ways. Direct physical trauma is transferred from adjacent fractures of the bony spine or its disrupted ligaments. Ischemia occurs from compression, bleeding and hypoperfusion of the spinal cord. At the cellular level, edema and free radical formation impair neuronal function. Various clinical syndromes may occur, depending on the spinal cord level involved (see "Spinal Cord Disorders"). Severe spinal cord trauma may cause the syndrome of **"spinal shock"** where the expected upper motor neuron signs on neurological examination are absent for weeks to months, and the patient has hypotonia and areflexia accompanying the paralysis. **High cervical spinal cord lesions** may produce quadriplegia with respiratory paralysis, since the diaphragm is innervated by C3, C4 and C5 nerve roots. Sympathetic pathways may also be involved, creating bradycardia, fluctuating blood pressure, and hypothermia. The **central cervical cord syndrome** usually occurs in elderly patients with advanced degenerative arthritis of the spinal column, who fall forward and hyperextend the neck. A central hemorrhage of the cervical spinal cord is produced, causing predominant weakness of the upper limbs by affecting the medial portion of the corticospinal tract (fibers controlling the upper limbs) and the cervical anterior horn cells.

As with head trauma care, patients with spinal cord injuries need emergent assessment of ABCs (airway, breathing, circulation) and initial immobilization of the neck until imaging studies rule out cervical fractures or dislocations. Neurological recovery is more likely if high-dose intravenous corticosteroids (dexamethasone) are begun within 8 hours of injury. Patients may need transport to a trauma center, especially if surgical decompression of the spine is emergently needed. Long term rehabilitation therapy follows.

5. Peripheral nerve injuries

Injury of a major nerve in a limb is suggested by a specific pattern of sensorimotor deficit. Electromyography (EMG) helps confirm the nerve involved and the severity of the lesion, but it may take 2-3 weeks to detect all the findings of denervation present. When a nerve appears to be totally severed, as from a serious penetrating injury or laceration, early surgical exploration may be worthwhile. Surgical reanastomosis or grafting of a severed nerve relies on nerve regrowth for recovery to occur, which optimally occurs at a rate of 1 inch per month. Thus, the prognosis is poorer for nerves which are severed more proximally. If there is blunt trauma to a peripheral nerve, some anatomical continuity may persist. Serial observation for spontaneous nerve regrowth without surgical intervention may be the best option in that case. Sometimes misdirected, regrowing axons may form a painful, swollen, bulbous ending (traumatic neuroma). A sympathetically mediated regional pain syndrome may develop and persist.

6. Neck and back pain

Neck and back pain are common problems which may result from chronic lifting, straining or bending, or more acutely from a specific trauma or injury. Local pain may be due to inflammation or stretching of ligaments, muscles or tendons related to the spinal column. Radicular pain in the upper or lower limb may occur also from nerve root irritation. Initial treatment consists of bed rest or "taking it easy" for a few days, with local heat, anti-inflammatory and analgesic medications. Persistent pain, particularly if accompanied by focal sensorimotor deficits, requires evaluation with imaging of the cervical or lumbar spine using MRI or CT myelography. Surgery may be indicated to remove a herniated intervertebral disc or arthritic, bony fragments compressing the neuroforamina. Some patients have persistent or recurrent pain after surgery, and become a difficult and challenging therapeutic dilemma.