

Cranial Nerves, Brain Stem Reflexes, and Brain Stem Disorders (Dr. Merchut)

Cranial Nerves and Brain Stem Reflexes

1. Olfactory Nerve (CN I)

Olfaction is usually not tested during a neurological examination unless the patient has mentioned a problem with the sense of smell. Testing is done by bringing an aromatic substance, such as an alcohol pad or packet of coffee grounds, to one nostril at a time, with the patient identifying the odor with eyes closed. Impaired smell most commonly occurs from the mucosal swelling and inflammation during sinusitis or an **upper respiratory infection**. A permanent loss of smell may occur after severe **head trauma**, where the olfactory nerve branches are sheared or torn where they pass through the bony cribriform plate. Another persistent loss of smell may be caused by a **tumor near the olfactory lobe** at the skull base, such as a meningioma.

2. Optic Nerve (CN II)

(CN II will be discussed in the section Visual, Auditory, and Vestibular Systems.)

3. Oculomotor (CN III), Trochlear (CN IV), and Abducens (CN VI) Nerves

Cranial nerves III, IV and VI innervate the extraocular muscles, which are tested by the patient tracking or following a target (examiner's finger or pen) up and down and side to side. Diagonal tracking may also be tested: looking up and rightward, looking down and rightward, looking up and leftward, and looking down and leftward. Observe and note the directions in which eye movements are limited or impaired---it may be difficult at first to localize the problem specifically to one of these cranial nerves, since some extraocular muscles have multiple actions because of their diagonally oriented insertion on the eyeball.

In this discussion of eye movements, the initial position of the eyeball is in primary gaze or "looking straight ahead." Since the superior and inferior oblique muscles insert more posteriorly on the eyeball, their contraction also abducts the eyeball: the superior oblique depresses and abducts the eye, while the inferior oblique elevates and abducts the eye (see Fig.1). Since the superior and inferior recti insert more anteriorly on the eyeball, their contraction also adducts the eyeball: the superior rectus elevates and adducts the eye, while the inferior rectus depresses and adducts the eye. (Here is the final part of the "picture," although at the risk of greater confusion: Muscles inserted on the top of the eyeball (superior rectus and superior oblique) will also rotate the eye medially or inward (intorsion), while muscles inserted on the bottom of the eyeball (inferior rectus and inferior oblique) will also rotate the eye laterally or outward (extorsion).) In contrast, two muscles have simple lateral actions on the eyeball: abduction by the lateral rectus and adduction by the medial rectus.

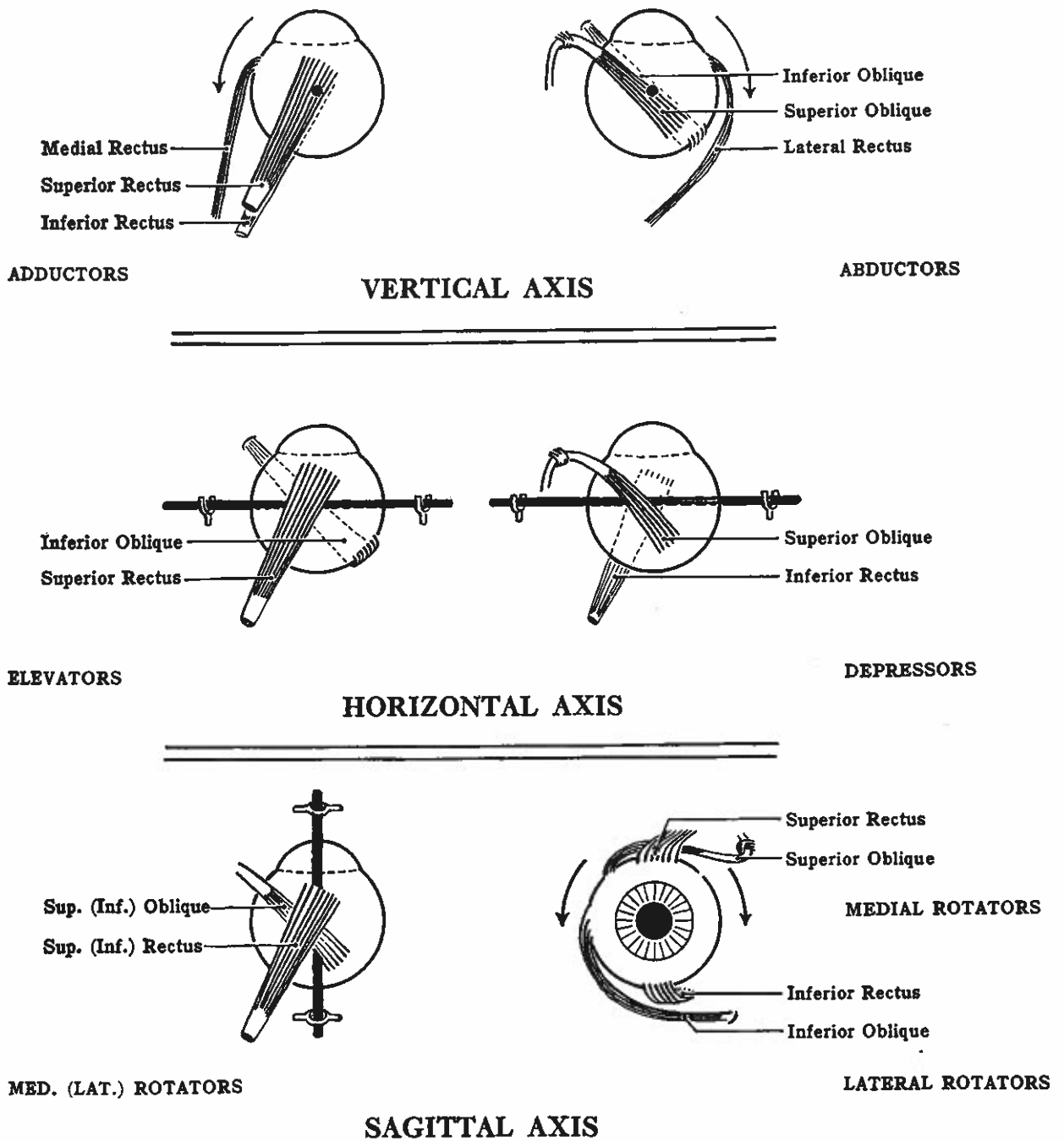


Fig. 1 Actions of the six extraocular muscles.
 The right eyeball is shown above (from Grant's Atlas of Anatomy, 6th ed., 1972).

Given the complex movements of the extraocular muscles that elevate or depress the eyeball, how can you best determine which muscle is malfunctioning? If elevation of the eye appears incomplete, the superior rectus or inferior oblique (or both) may be weak. When the patient turns this eye inward (adduction), weakness of elevation from this

starting position is mainly due to the inferior oblique, since the adducted eyeball is aligned parallel to this muscle. When the patient turns this eye outward (abduction), weakness of elevation from this starting position is mainly due to the superior rectus. On the other hand, if depression of the eye appears incomplete, the superior oblique or inferior rectus (or both) may be weak. Thus, when the patient turns this eye outward (abduction), weakness of depression from this starting position is mainly due to the inferior rectus. When the patient turns this eye inward (adduction), weakness of depression from this starting position is mainly due to the superior oblique. Examining in this manner is referred to as testing the "cardinal directions of gaze," where eye depression or elevation is isolated to a single extraocular muscle, since the eye begins moving from a starting position of abduction or adduction, not from primary "straight ahead" gaze.

Starting position	Action tested by examiner	Corresponding single muscle tested
Out (abducted)	Eye elevation	Superior rectus
Out (abducted)	Eye depression	Inferior rectus
In (adducted)	Eye elevation	Inferior oblique
In (adducted)	Eye depression	Superior oblique
Out	Eye abduction	Lateral rectus
In	Eye adduction	Medial rectus

Table 1. Cardinal Directions of Gaze: positions in which only a single extraocular muscle is tested in isolation.

Clinically, the deficit from a complete **oculomotor nerve (CN III) lesion** is usually striking (see Fig. 2). Paralysis of the levator palpebrae superioris muscle may cause such complete **ptosis** that the ipsilateral drooping eyelid entirely covers the eye. If the eyelid is passively pulled up, the involved eye tends to be somewhat abducted or outwardly deviated because of the unopposed action of the lateral rectus muscle. Indeed, the patient is **only able to abduct the eye** since the abducens nerve is spared. The **pupil of the involved eye is large and unreactive to light**, directly or consensually, since the parasympathetic innervation of the pupil is impaired. The trochlear (CN IV) nerve is the only cranial nerve which exits the brain stem dorsally, and decussates to innervate the contralateral superior oblique muscle. A trochlear nerve (CN IV) lesion produces a subtle deficit that is difficult to detect clinically. Impairment of downward gaze (depression of the eyeball) is best noted when the involved eye is in the adducted position. An **abducens nerve (CN VI) lesion** affects only the ipsilateral lateral rectus muscle, impairing abduction of the affected eyeball.

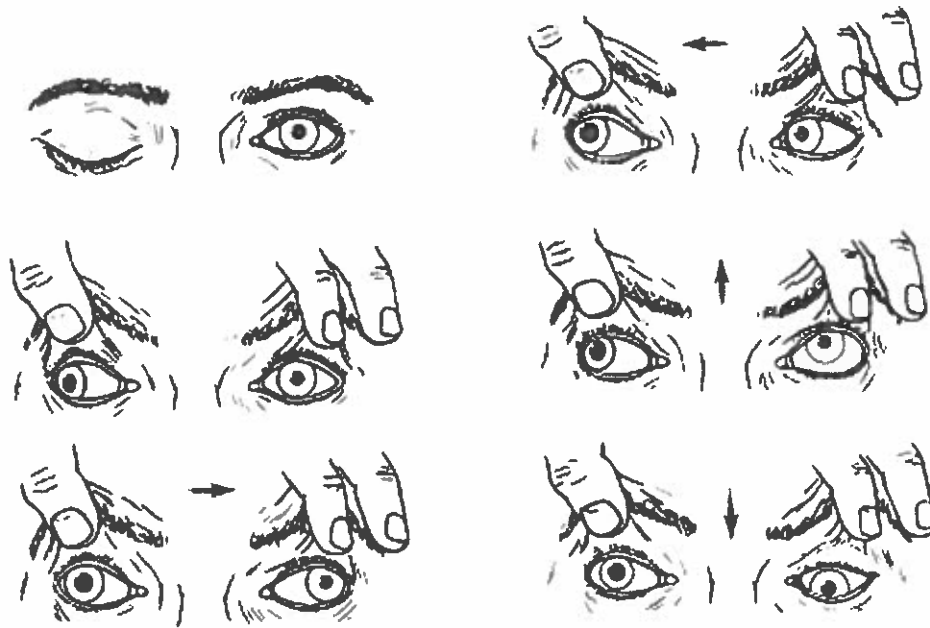


Fig. 2 Complete lesion of right CN III. The patient is asked to look in the directions of the arrows (from Rodnitzky RL. Van Allen's pictorial manual of neurologic tests. 3rd ed. Chicago:Year Book Medical, 1988)

4. Eye movement disorders

Normal binocular vision depends on analogous or equivalent areas of the retina of each eye perceiving the same visual stimulus. If the eyeballs are not perfectly aligned in primary position ("looking straight ahead") or when conjugately moving to other positions, a visual image may appear blurred or doubled (binocular diplopia). **Binocular diplopia** is the more common type of diplopia and **resolves if the patient covers either eye**. It can be caused by lesions of cranial nerves III, IV or VI, or their related extraocular muscles (or neuromuscular junctions therein). In the case of a severe or complete oculomotor nerve lesion, however, diplopia would be eliminated by the ptosis covering the involved eye. There are also connecting pathways within the brain stem which coordinate the actions of these extraocular muscles, plus connections with the vestibular and cerebellar systems allowing for smooth, reflexive eye movements as well. Thus, lesions involving these brain stem or cerebellar connections could also cause diplopia. **Monocular diplopia** is relatively rare and **occurs when looking with one eye alone**. It may occur from a problem in the "optical system" of an eye, such as a dislocated lens or detached retina, or may be related to a psychiatric disorder, but not from neurological disease, strictly speaking.

Patients complaining of diplopia may also be noted to have **nystagmus**, which refers to repetitive, oscillatory, jerky eye movements. Nystagmus can be physiological or normally induced, as when suddenly stopping someone rotating in a swivel chair.

Pathological or abnormal nystagmus occurs with lesions of the vestibular system, brain stem, or cerebellum which upset the normal control or balance of conjugate eye movements. Such lesions typically produce asymmetrical nystagmus, more prominent with certain eye movements or positions, while nystagmus caused by drug toxicity usually is symmetrical and present with virtually all eye movements or positions. For example, a vestibular lesion produces horizontal nystagmus, with a slow component or eyeball jerk toward the side of the lesion, and a fast component in the other direction.

Internuclear ophthalmoplegia (INO) refers to the paralysis of extraocular muscles ("ophthalmoplegia") from a lesion between the nuclei ("internuclear") involved with lateral gaze (oculomotor and abducens nuclei). Such a lesion interrupts the **ascending medial longitudinal fasciculus (MLF)**, and therefore this disorder is also called the **MLF syndrome**. To have coordinated horizontal gaze rightward, for example, the right paramedian pontine reticular formation (PPRF) must activate both the right abducens nucleus in the pons and the left oculomotor nucleus in the midbrain, so that the right lateral rectus and left medial rectus muscles move the eyes to the right. The ascending MLF leaves the right PPRF, decussates early and rises to join the left oculomotor nucleus. A lesion along the main left-sided course of the MLF here, en route from pons to midbrain, produces paralysis of adduction of the left eye, with nystagmus of the abducting right eye (see Fig. 3). Since the left oculomotor nucleus never gets the "MLF signal," the left eye cannot adduct and right lateral gaze is impaired. However, the left medial rectus still functions, since both eyes adduct or converge when looking closely at an object (the near reflex, described below). **The most common causes of MLF lesions are multiple sclerosis in younger patients and ischemic infarction in older patients.**

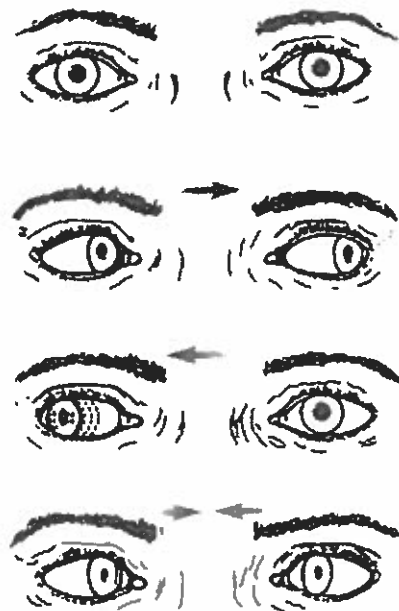


Fig. 3 Left MLF syndrome with attempted gaze in the direction of the arrows (from Rodnitzky RL. Van Allen's pictorial manual of neurologic tests. 3rd ed. Chicago:Year Book Medical, 1988)

5. Disorders of the pupil

Abnormalities of the pupil are discussed here since they are often encountered with lesions of the cranial nerves or pathways associated with eye movements. The normal **pupillary light reflex** is elicited by shining light into one eye, causing not only its pupil to constrict (direct response) but also that of the other eye (consensual response). This reflex pathway involves retinal ganglion cells projecting bilaterally to the pretectal area (rostral to the superior colliculus), which then projects to the Edinger-Westphal nucleus of CN III. For example, a left optic nerve lesion impairs the afferent part of this consensual reflex, so neither pupil constricts when light is shined into the left eye, yet both pupils constrict when light is shined into the right eye. A right CN III lesion interrupts the efferent part of this consensual reflex, so the enlarged right pupil never constricts when light is shined in either eye, yet the left pupil constricts with light shined in either eye.

A **relative afferent pupillary defect (RAPD)** may occur from a partial optic nerve or retinal lesion. Both pupils may initially constrict to light, but after moving the light source from the normal to the abnormal eye ("swinging flashlight test"), pupillary dilatation occurs because of relatively reduced afferent input at the affected eye. If one were to observe both eyes simultaneously, the light stimulus produces direct and consensual pupillary constriction, but to a lesser degree when the affected eye is stimulated.

The **near reflex** occurs when viewing a nearby object and normally consists of pupillary constriction, lens accommodation ("thickening"), and convergence of the eyes. In certain disorders, there is selective disruption of the pupillary light reflex pathway at the superior colliculus or pretectal area, but connections for the near reflex are preserved. This creates **dissociation of light and near reflexes (light-near dissociation)** such that the pupils only constrict during the near reflex, but not to a light stimulus. Classic causes of light-near dissociation include the dorsal midbrain syndrome and the Argyll Robertson pupils in neurosyphilis. The dorsal midbrain (Parinaud's) syndrome classically refers to a pineal tumor compressing the dorsal midbrain but may also occur from an ischemic infarction there. As the midbrain centers for vertical gaze may be also involved in this syndrome, impairment of upward gaze may accompany light-near dissociation of the pupils.

Horner's syndrome occurs from a lesion disrupting the oculosympathetic pathway, causing **miosis** (a smaller, constricted pupil which dilates poorly in darkness), **anhidrosis** (decreased sweating in the ipsilateral face since sweat glands have sympathetic innervation), and mild **ptosis** (paralysis of the superior tarsal muscle). The oculosympathetic pathway is relatively long and consists of three neurons in series. First-order neurons descending down the brain stem may be involved by a lateral medullary infarction (Wallenberg syndrome). Second-order neurons originating from the intermediolateral cell column in the spinal cord at C8 to T2 levels may be affected by a tumor as they course through the apex of the lung. Third-order neurons arising from the superior cervical sympathetic ganglion ascend up the internal carotid artery where they may be affected by neck trauma. It should be noted that the ptosis in Horner's syndrome is subtle and mild in comparison to the more obvious ptosis from an oculomotor (CN III) nerve lesion.

6. Trigeminal Nerve (CN V)

The trigeminal nerve has sensory and motor functions. Sensation over the face and anterior scalp is conveyed to the brain stem by three divisions or branches: **V-1 (ophthalmic)**, **V-2 (maxillary)**, and **V-3 (mandibular)**. These branches may be compressed by tumors particularly where they pass through bony foramina in the skull base, or may be affected by infection or inflammation there. A V-1 sensory deficit over the forehead (see Fig. 4) should also involve the anterior scalp, while a V-3 sensory deficit should not involve the corner of the jaw or the neck. Thus, sensory deficits not confined to the trigeminal nerve territory may be due to lesions in the contralateral thalamus or parietal lobe, or may be associated with psychiatric disorders. Trigeminal branch sensory deficits may accompany other cranial nerve lesions. A V-1 territory sensory impairment plus ipsilateral involvement of cranial nerves III, IV and VI may occur from a lesion at the superior orbital fissure or nearby cavernous sinus.

Trigeminal neuralgia is a painful syndrome of irritation or inflammation of one of the trigeminal nerve sensory branches which "short circuits" or "misfires." Patients experience episodic, lightning-like jabs or "electrical shocks" of pain usually in the territory of V-2 or V-3, several times daily, provoked by talking, chewing or touching the face. No sensory or other cranial nerve deficits are found on neurological examination however. A multiple sclerosis lesion at the trigeminal nerve entry region into the pons is often the cause in younger patients. In older patients, a trigeminal nerve branch is often compressed by a tortuous or kinked blood vessel (often the superior cerebellar artery), which can be surgically repositioned or padded. Other treatments include oral anticonvulsants such as carbamazepine, gabapentin or others to relieve the nerve "misfiring" or procedures to destroy the nerve branch involved.

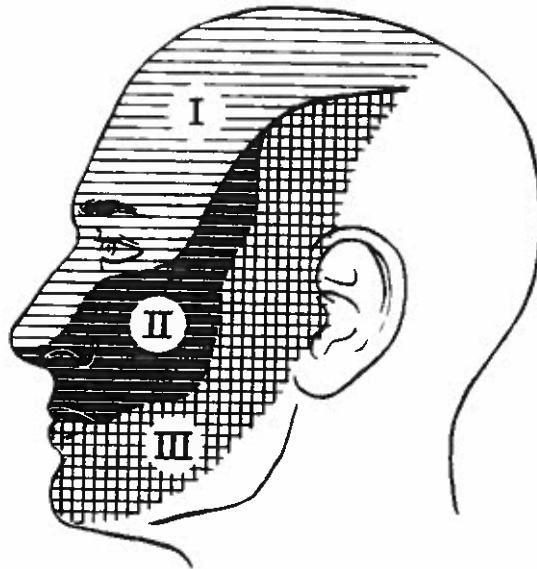


Fig. 4 Trigeminal nerve sensory territories: V-1 (V-I) Ophthalmic, V-2 (V-II) Maxillary, and V-3 (V-III) Mandibular (from Rodnitzky RL. Van Allen's pictorial manual of neurologic tests. 3rd ed. Chicago:Year Book Medical, 1988)

The trigeminal nerve also innervates the muscles of chewing or mastication---the masseter and temporalis muscles. A lower motor neuron lesion of the trigeminal motor nerve is rare and produces atrophy and weakness in these ipsilateral muscles, with the jaw deviating toward the side of the lesion. Both ipsilateral and contralateral upper motor neurons in the motor cortex control the trigeminal motor nerve on one side, so an upper motor neuron lesion on one side does not produce any jaw deviation or severe weakness. Bilateral upper motor neuron lesions here, however, may cause **hyper-reflexia of the jaw jerk**, since it is a muscle stretch reflex (tested by gently tapping on the chin with the mouth slightly opened and relaxed).

7. Facial Nerve (CN VII)

Each facial nerve, originating from its facial nucleus in the pons, innervates the ipsilateral facial muscles, from uppermost frontalis to lowermost platysma. **A lower motor neuron facial paralysis involves the nucleus or nerve of CN VII and causes a relatively severe paralysis of the entire ipsilateral half of the face.** This would be the isolated finding with a lesion at or near the stylomastoid foramen (see lesion 1 in Fig. 5). Other signs and symptoms accompany facial nerve lesions within the temporal bone. Ipsilateral facial paralysis plus **impaired taste over the anterior 2/3 of the tongue indicates that the chorda tympani branch of the facial nerve is also involved** (lesion 2A in Fig. 5), while a slightly more proximal lesion (lesion 2B in Fig. 5) also involves the facial nerve branch to the stapedius muscle. The stapedius muscle acts to dampen middle ear ossicle movements in the presence of loud sounds, so an unpleasant sensitivity to sound (**hyperacusis**) is a symptom of stapedius muscle denervation. A lesion at the internal auditory meatus or **cerebellopontine angle** would create all the deficits as in lesion 2B plus hearing impairment and tinnitus, an unpleasant, persistent ringing or buzzing sound or pitch, from involvement of the adjacent CN VIII. This lesion (lesion 3 in Fig. 5) is often from an acoustic neuroma, a tumor arising from CN VIII. A lesion at or near the facial nucleus in the pons (lesion 4 in Fig. 5), such as a small ischemic infarction, would most likely also create ipsilateral weakness of lateral gaze, from involvement of the adjacent PPRF and CN VI.

In addition to tumors or trauma causing lesions of CN VII in its course outside the pons, a very common syndrome is **Bell's palsy** or idiopathic facial nerve paralysis. The patient may awaken to suddenly notice severe paralysis of one side of the face, sometimes with ipsilateral hyperacusis and impaired taste. A short course of oral corticosteroid medication hastens recovery from the presumed facial nerve inflammation where it travels through the temporal (petrous) bone. Herpes simplex or other viruses may cause this inflammation, so anti-viral medication may also be part of the treatment. In general, most patients with Bell's palsy recover fully after a few weeks.

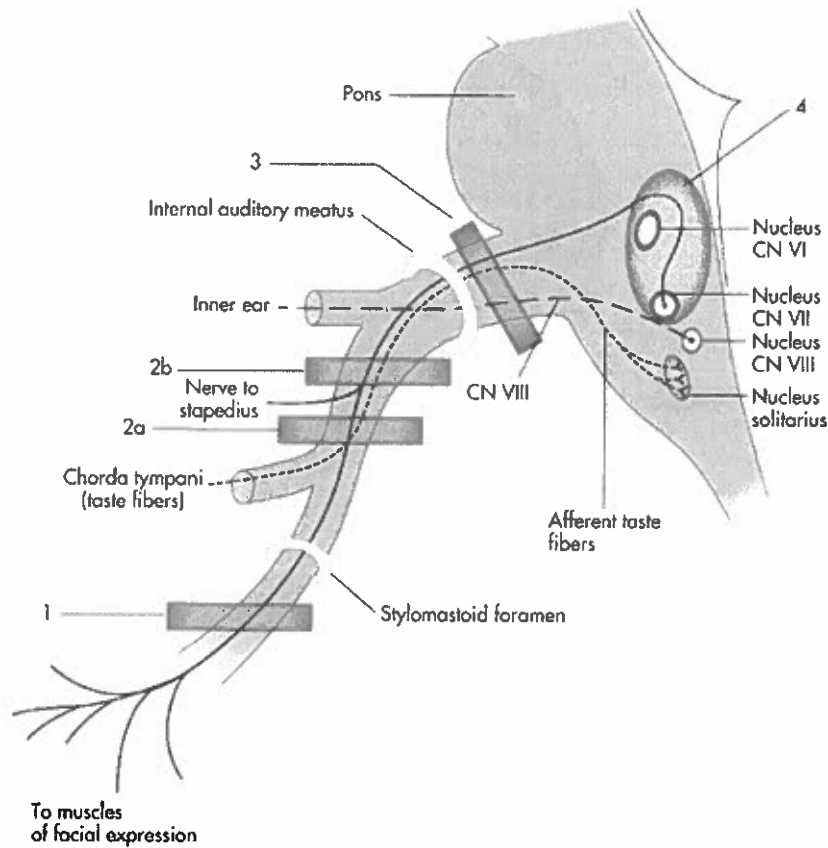


Fig. 5 Nuclear and infranuclear lesions of the facial nerve.

Facial paralysis may also occur with lesions of the upper motor neurons that control the facial (CN VII) nucleus. The part of the CN VII nucleus which innervates the upper face or forehead is controlled by upper motor neurons (corticobulbar tract fibers) originating both ipsilaterally and contralaterally, while the rest of the CN VII nucleus is controlled only by contralateral upper motor neurons (see Fig. 6). Thus, **facial paralysis from an upper motor neuron lesion causes a relatively milder paralysis of only the lower part of the contralateral face, sparing the forehead.**

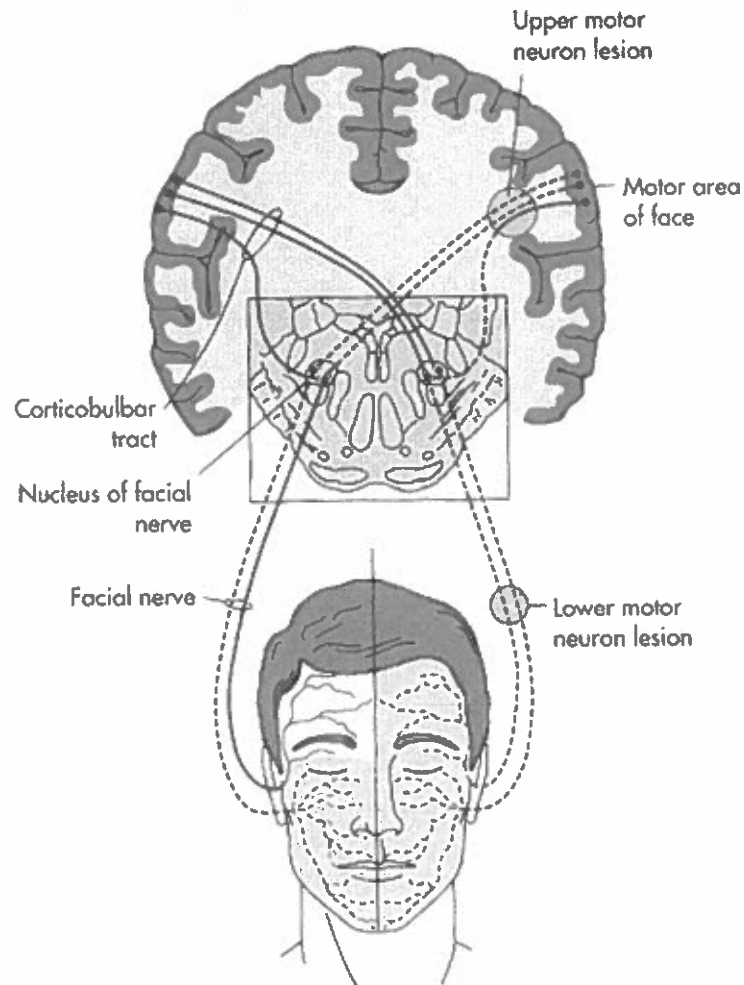


Fig. 6 Upper versus lower motor neuron facial paralysis. The shaded areas of the face show the distribution of the facial muscles paralyzed after a supranuclear lesion of the corticobulbar tract (upper motor neuron lesion) and after a lesion of the facial nerve or its nucleus (lower motor neuron lesion) (from Gilman S, Winans SS. *Manter and Gatz's essentials of clinical neuroanatomy and neurophysiology*. 6th ed. Philadelphia: FA Davis, 1982)

8. Vestibulocochlear Nerve (CN VIII)

(CN VIII will be discussed in the section Visual, Auditory, and Vestibular Systems.)

9. Glossopharyngeal (CN IX) and Vagus (CN X) Nerves

Cranial nerves IX and X have similar or shared functions, but taste, visceral afferent, and visceral efferent functions cannot be tested clinically. Both nerves innervate

pharyngeal and laryngeal muscles, so glossopharyngeal or vagus nerve lesions can cause impairments of speech or swallowing, but it is often difficult to test each nerve separately. A decreased or absent **gag reflex** when touching one side of the pharynx suggests a glossopharyngeal nerve lesion on that side. The gag reflex is difficult to evaluate, however, since some patients virtually never gag, while others are very sensitive to pharyngeal stimulation and hate being tested. Elevation of the palatal arch is readily observed when asking the patient to say "ah" (see Fig. 7) and reflects vagal nerve function. A **lower motor neuron lesion of vagal nerve** branches innervating the palate causes **ipsilateral drooping or sagging of the palatal arch** with the uvula pointing toward the other (normal) side. A **lower motor neuron lesion of vagal nerve** branches innervating the larynx causes **hoarseness** from ipsilateral paralysis of vocal cord muscles.

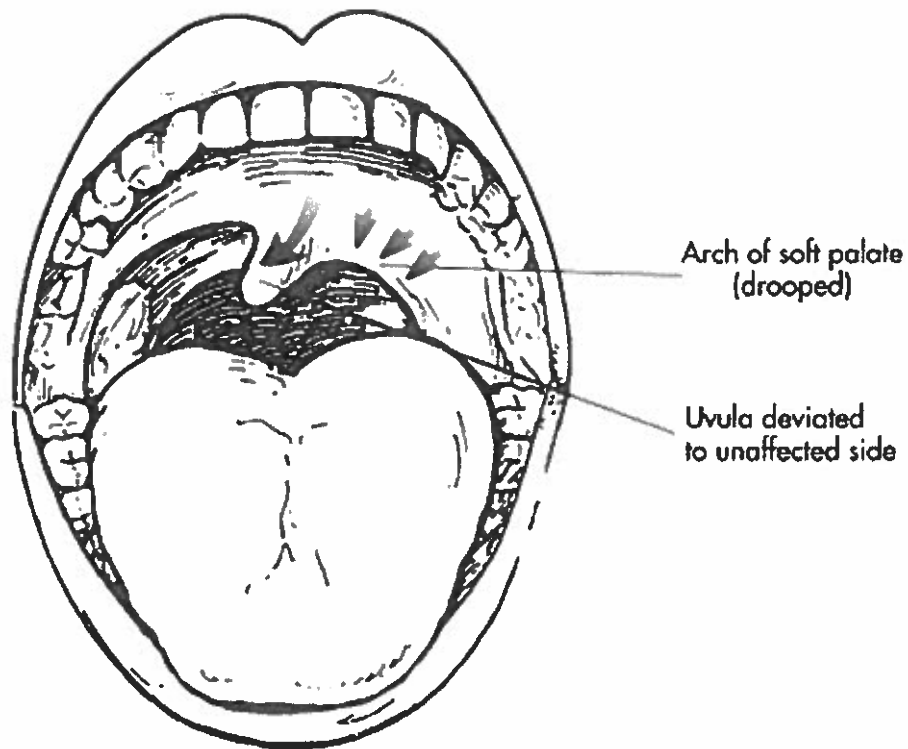


Fig. 7 A lesion of the left vagal nerve branches innervating the soft palate.

10. Spinal Accessory Nerve (CN XI)

A lower motor neuron lesion of CN XI weakens the ipsilateral sternocleidomastoid and trapezius muscles, which it innervates. Decreased elevation or shrugging of the shoulder is observed along with weakness in turning the head to the opposite side.

11. Hypoglossal Nerve (CN XII)

The hypoglossal nerve innervates the muscles of the tongue on each side. Most important for clinical testing is the genioglossus muscle, which protrudes each side of the tongue forward. **A lower motor neuron lesion of CN XII on one side causes the protruded tongue to deviate or turn toward the affected or weak side**, since the contralateral genioglossus muscle normally pushes its half of the tongue forward. Over time, the affected half of the tongue would **atrophy and fasciculations and fibrillations** would be observed there. In a few patients, the upper motor neurons (corticobulbar tract fibers) controlling the CN XII nucleus only arise contralaterally. In that case, an ischemic infarction of the left frontal lobe would impair the right hypoglossal nucleus, weakening protrusion of the right half of the tongue such that the **protruded tongue may deviate or turn toward the side opposite its upper motor neuron lesion**. In most patients, however, ipsilateral and contralateral upper motor neurons control each hypoglossal nucleus, so a frontal lobe lesion on one side would not cause weakness or deviation of the tongue.

Brain Stem Disorders

1. Types of cranial nerve lesions

One or more cranial nerves may be impaired by various kinds of pathology in their anatomical vicinity, such as tumors or fractures of the skull base, or infection or inflammation of the meninges. Polyneuropathies affecting multiple nerves in the limbs and trunk, caused by diabetes or the Guillain-Barre syndrome, may also involve cranial nerves. All these lesions involve one or more cranial nerves outside the brain stem.

Lesions within the brain stem itself often are from ischemic infarction, hemorrhage, tumor or multiple sclerosis. It would be unusual for one of these disorders to just involve a cranial nerve or two inside the brain stem. Most often anatomically adjacent fiber tracts are also involved.

2. Brain stem syndromes

Crossed brain stem syndromes consist of **cranial nerve involvement on one side and an adjacent fiber tract lesion, creating a clinical sensory or motor deficit on the opposite side of the body**. These clinical findings help localize the problem to a particular area or level of the brain stem. For example, a right pontine lesion involves the right facial nucleus and the right corticospinal tract, creating a lower motor neuron paralysis of the entire right half of the face plus an upper motor neuron paralysis of the left upper and lower limbs (left hemiparesis). Another example is a lesion in the left lateral medulla which involves the left descending spinal tract of CN V and the left spinothalamic tract, which consists of afferents from the right side of the spinal cord that have already decussated within the cord itself. The unusual clinical features include deficits of pain (pinprick) and temperature over the left face and right limbs and body. Two well-known crossed brain stem syndromes are discussed below.

The **medial midbrain syndrome (Weber syndrome)** may be due to an ischemic infarction from an occluded branch of the posterior cerebral artery. CN III and the nearby cerebral peduncle (corticospinal and corticobulbar tracts) are involved, creating an **ipsilateral oculomotor nerve lesion and upper motor neuron weakness of the contralateral face and limbs.**

The **lateral medullary syndrome (Wallenberg syndrome)** may be due to an ischemic infarction from an occluded vertebral artery or its PICA (posterior inferior cerebellar artery) branch. The features making it a "crossed brain stem syndrome" are **pain (pinprick) and temperature impairment in the ipsilateral face and contralateral limbs and body**, as explained above. Other symptoms may include hoarseness, vertigo, nausea and vomiting, and clumsiness. In addition to the sensory deficits mentioned, other signs may include nystagmus (vestibular nuclei), ipsilateral limb dysmetria (inferior cerebellar peduncle), ipsilateral Horner's syndrome (descending sympathetic tract), and ipsilateral palatal and vocal cord paralysis (nucleus ambiguus). It should be noted that in this syndrome position sense and strength are preserved.